

## Near-Infrared Imaging of Veins in Facial Injection of Botulinum Toxin and Hyaluronic Acid

GUILLERMO BLUGERMAN, MD,\* DIEGO SCHAVELZON, MD,\* AND JULIÁN ÁLVAREZ, MD†

*The authors have indicated no significant interest with commercial supporters.*

The efficacy of the application of botulinum toxin type A (BTX-A) and hyaluronic acid (HA) as minimally invasive treatments in facial rejuvenation has been previously demonstrated.<sup>1,2</sup> The local side effects most frequently observed are pain, swelling, erythema, and bruising.<sup>1-4</sup> In spite of the limited and benign nature of these events, they usually cause discomfort for the patient who is looking for aesthetic improvement.

### Materials and Methods

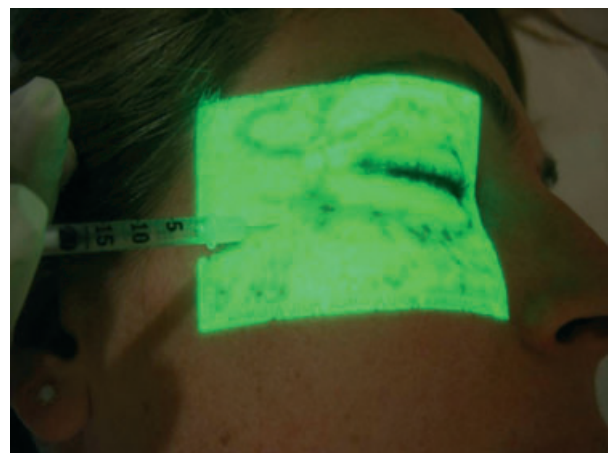The Vein Viewer (VV) (Luminetx Corp., Memphis, TN) is a device designed to project the enhanced image of the subcutaneous veins onto the skin. VV operates through near-infrared light emission that is scattered in the skin and subcutaneous fat, while it is partially absorbed in venous blood flow. A camera captures the outcome emission, and the image, processed by computer, is projected onto the skin surface as a green light.<sup>5</sup>

Optimal performance is achieved when the image is in focus and when the axis of the emission is perpendicular to the surface of the skin. With this technique, not-apparent subcutaneous veins are easily identified. Its use has been described for vascular identification in peripheral venous disease, as

adjuvant in venipuncture of children, and in difficult venous access.<sup>5,6</sup>

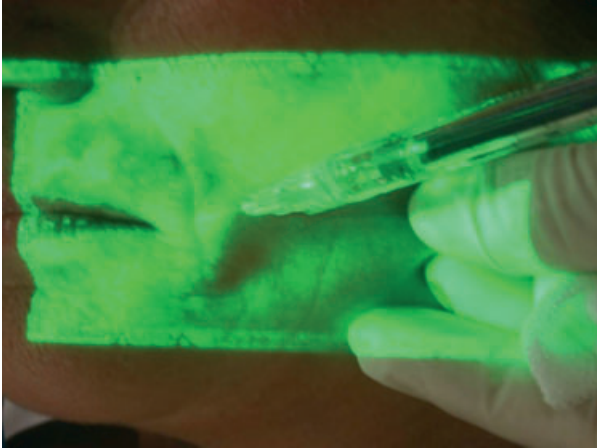
We propose the use of this vein imaging device to avoid accidental puncture of the vessels in facial injection of BTX-A and fillers to reduce bruising and to prevent intravascular injection and to consider the risk of external compression by fillers in high-risk zones for vascular occlusion, such as the glabella and the nasal wing.<sup>7</sup>

The device has been used in two ways: direct use during the injection process (Figures 1 and 2) and using the device to map the vessels before the pro-

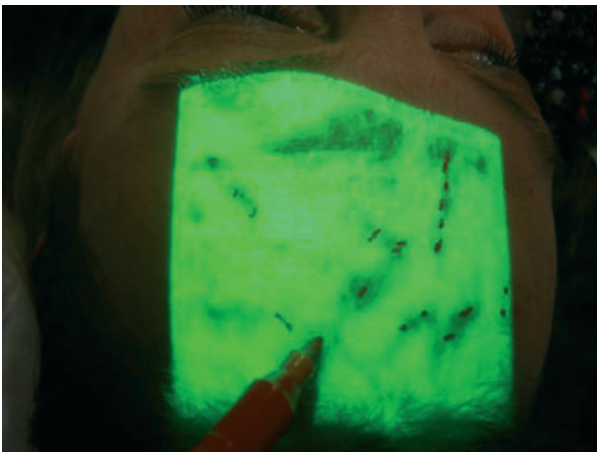


**Figure 1.** Direct use of near-infrared device during botulinum toxin injection for periorbital rhytids.

\*Centro B & S Excelencia en Cirugía Plástica, Buenos Aires, Argentina; †Aesthetic Medicine Residency Program, Universidad del Rosario, Bogotá, Colombia



**Figure 2.** Direct use of the machine in the implant of filler material (hyaluronic acid) in nasolabial folds.



**Figure 3.** Marking vein pattern with skin marker before procedure.

cedure (Figure 3). In the second use, we use a removable skin marker (Dermarker, Viscot Medical, East Hanover, NJ) to identify the injection points. The mark is easily erased after treatment.

## Conclusion

The use of this technology in our patients should reduce the incidence of secondary effects (mainly hematoma), help to prevent serious complications such as vascular occlusion, and improve results of minimally invasive facial treatments such as BTX-A and fillers injections.

## References

1. Carruthers JD, Lowe NJ, Menter MA, Gibson J, et al. Double-blind, placebo-controlled study of the safety and efficacy of botulinum toxin type A for patients with glabellar lines. *Plast Reconstr Surg* 2003;112(Suppl):21S-30S.
2. Monheit GD, Coleman KM. Hyaluronic acid fillers. *Dermatol Ther* 2006;19:141-50.
3. Sommer B. How to avoid complications when treating hyperdynamic folds and wrinkles. *Clin Dermatol* 2003;21:521-3.
4. Vartanian AJ, Dayan SH. Complications of Botulinum toxin A use in facial rejuvenation. *Facial Plast Surg Clin North Am* 2003;11:483-9.
5. Miyake RK, Zeman HD, Duarte FH, Kikuchi R, et al. Vein imaging: a new method of near Infrared imaging, where a processed image is projected onto the skin for the enhancement of vein treatment. *Dermatol Surg* 2006;32:1031-8.
6. Strehle EM. Making the invisible visible: near-infrared spectroscopy and phlebotomy in children. *Telemed J E Health* 2010;16:889-93.
7. Grunembaum LD, Allemann IB, Dayan S, Mandy S, et al. The risk of alar necrosis associated with dermal filler injection. *Dermatol Surg* 2009;35:1635-40.

---

Address correspondence and reprint requests to:  
Guillermo Blugerman, MD, Centro B & S Excelencia en  
Cirugía Plástica, Laprida 1579, Buenos Aires, Argentina,  
or e-mail: blugerman@centrosbys.com