

Targeting Reflux-Free Veins with a Vein Visualizer to Identify the Ideal Recipient Vein Preoperatively for Optimal Lymphaticovenous Anastomosis in Treating Lymphedema

Johnson Chia-Shen Yang, M.D.
 Shao-Chun Wu, M.D.
 Min-Hsien Chiang, M.D.
 Wei-Che Lin, M.D.
 Kaohsiung, Taiwan



Summary: Lymphaticovenous anastomosis is one of the main surgical treatments nowadays for alleviating lymphedema. A successful lymphaticovenous anastomosis relies on being able to identify “functional” lymphatic collecting vessels that are still capable of transporting lymph, and a nearby vein that is, ideally, reflux-free. This is a retrospective study. A total of 28 lymphedema patients were enrolled from October of 2016 to March of 2017 in Kaohsiung Chang Gung Hospital, Kaohsiung, Taiwan. A noninvasive vein visualizer was used to preselect reflux-free veins for lymphaticovenous anastomosis from five female patients. As a control, the total number of veins used for lymphaticovenous anastomoses without the use of a vein visualizer from 23 consecutive lymphedema patients was also recorded and compared. In the experimental group, a total of 12 of 13 veins (92 percent sensitivity) preselected by using the VeinViewer were confirmed to be reflux-free intraoperatively during lymphaticovenous anastomosis. In the control group, 21 of 56 veins (37.5 percent sensitivity) showed no venous reflux. Statistical analysis with the chi-square test showed a value of $p < 0.001$ (number needed to treat = 2.706). The odds of identifying reflux-free veins can be increased significantly with the use of a vein visualizer. (*Plast. Reconstr. Surg.* 141: 793, 2018.)

CLINICAL QUESTION/LEVEL OF EVIDENCE: Diagnostic, II.

Lymphedema is a disease where accumulation of lymph, mostly because of obstruction or destruction of the lymphatic system at the proximal site, can lead to swollen, heavy, painful, and infection-prone limbs. The introduction of lymphaticovenous anastomosis as early as the 1960s by Yamada¹ has shed light on and given hope for a disease that was once almost impossible to treat. By anastomosing lymphatic collecting vessels to recipient veins, the accumulated lymph can be drained back into the venous system, thereby relieving lymphedema.

A successful lymphaticovenous anastomosis relies on two key components: (1) being able to identify “functional” lymphatic collecting vessels, which are still capable of transporting lymph; and (2) a nearby vein that is, ideally, reflux-free. Because venous pressure is usually higher than lymphatic collecting vessel pressure,^{2,3} a recipient vein with reflux can flood back into the lymphatic collecting vessel after lymphaticovenous anastomosis. This can lead to a lower long-term lymphaticovenous anastomosis patency rate, as

From the Division of Plastic and Reconstructive Surgery, Department of Surgery, the Department of Anesthesiology, and the Department of Diagnostic Radiology, Kaohsiung Chang Gung Memorial Hospital and Chang Gung University College of Medicine.

Received for publication May 13, 2017; accepted October 4, 2017.

Presented at the 26th World Congress of Lymphology, in Barcelona, Spain, September 25 through 29, 2017.

Copyright © 2017 by the American Society of Plastic Surgeons

DOI: 10.1097/PRS.0000000000004176

Disclosure: *The authors have no financial interest to disclose. No funding was received for this article.*

Supplemental digital content is available for this article. Direct URL citations appear in the text; simply type the URL address into any Web browser to access this content. Clickable links to the material are provided in the HTML text of this article on the *Journal's* website (www.PRSJournal.com).

Table 1. Patient Summary

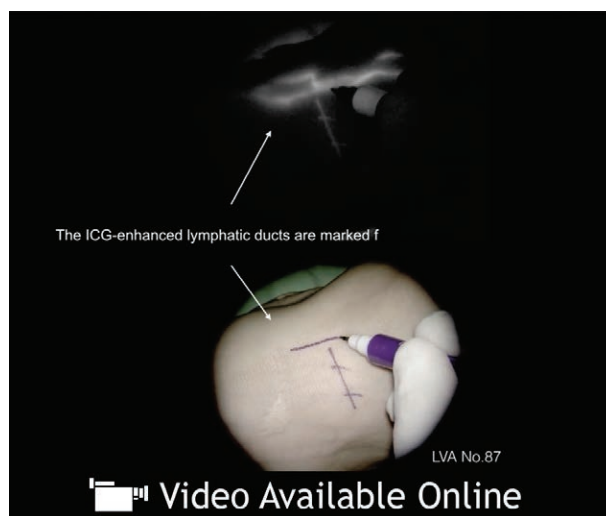
Characteristic	VeinViewer Group	Control Group
Age, yr		
Average	49	62
Range	40–63	36–81
Sex		
Male	—	2
Female	5	21
ISL staging	I–II	II–III
Affected limbs		
Upper	2	6
Lower	4	15
Lymphedema cause		
Breast cancer	2	6
Ovarian cancer	1	7
Endometrial cancer	2	4
Renal cell carcinoma		1
Primary biliary cirrhosis		1
Infection		1
Congenital		1
Reflux-free vein found	12/13 (92% sensitivity)	21/56 (37.5% sensitivity)

ISL, International Society of Lymphology.

stated by Yamamoto and Koshima.⁴ The identification of functional lymphatic collecting vessels with the use of indocyanine green has been published extensively.^{5–18} The localization of a recipient vein with a vein visualizer for lymphaticovenous anastomosis was published by Mihara et al.^{10,19} However, to the best of our knowledge, a publication regarding the identification of a reflux-free vein for lymphaticovenous anastomosis has yet to surface. In this study, the feasibility for using a noninvasive vein visualizer to identify a reflux-free vein for lymphaticovenous anastomosis preoperatively is demonstrated.

PATIENTS AND METHODS

This retrospective study was approved by the institutional review board of Chang-Gung Memorial Hospital (approval number 201700705B0), and all medical records were collected retrospectively. From October of 2016 to March of 2017 in Kaohsiung Chang Gung Hospital, Kaohsiung, Taiwan, a total of 28 lymphedema patients were enrolled and received supermicrosurgical lymphaticovenous anastomosis. A noninvasive vein visualizer (VeinViewer; Christie Medical, Memphis, Tenn.) was used to select reflux-free veins for lymphaticovenous anastomosis from five female patients as the experimental group. As the control, the total number of veins used for lymphaticovenous anastomosis from 23 consecutive lymphedema patients without the use of a vein visualizer was also recorded (Table 1).



Video 1. Supplemental Digital Content 1 demonstrates the marking of a functional lymphatic collecting vessel on the dorsal foot after indocyanine green (ICG) being injected intradermally. The enhanced lymphatic collecting vessel was observed under a microscope-integrated near-infrared camera, <http://links.lww.com/PRS/C663>.

Statistical Analysis

The chi-square or Fisher's exact test was used to compare the rates of reflux-free veins found in both vein visualizer and control groups. A value of $p < 0.05$ was considered to indicate a statistically significant difference. The number needed to treat with the use of the VeinViewer was calculated, which represents the minimal numbers in screening each vein to discover one reflux-free vein.

How to Identify a Reflux-Free Vein Using a Vein Visualizer

Indocyanine green was injected intradermally into the web spaces of each lymphedema patient's hand or foot, and at the wrist/ankle area. First, the indocyanine green-enhanced functional lymphatic collecting vessel was traced and marked with a microscope-integrated near-infrared camera (Pantero 900; Carl Zeiss AG, Oberkochen, Germany). [See Video, Supplemental Digital Content 1, which demonstrates the marking of a functional lymphatic collecting vessel on the dorsal foot after indocyanine green (ICG) being injected intradermally. The enhanced lymphatic collecting vessel was observed under a microscope-integrated near-infrared camera, <http://links.lww.com/PRS/C663>.] The region of premarked lymphatic collecting vessels was then placed under the VeinViewer (Fig. 1). Veins proximal to the premarked lymphatic collecting vessel are tested in series with milking tests, until an ideal reflux-free

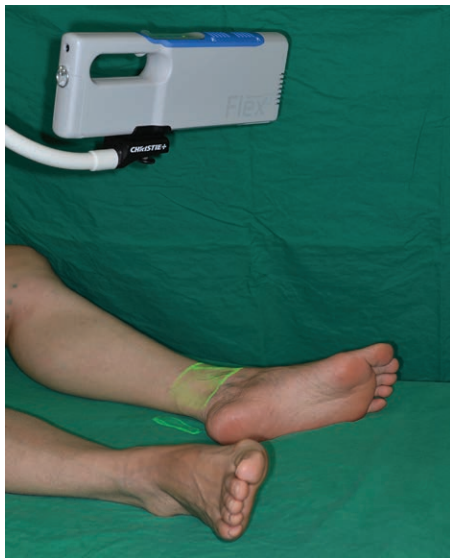

Fig. 1. Positioning of the vein visualizer for identification of the recipient vein on the left medial ankle before lymphaticovenous anastomosis.

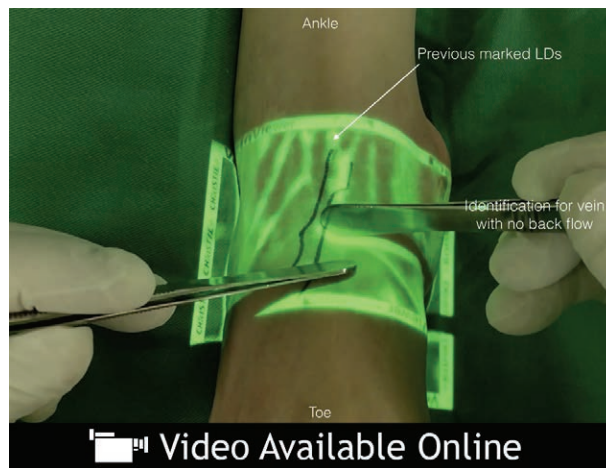
vein can be found. (See Video, Supplemental Digital Content 2, which demonstrates how to find a reflux-free vein with the milking test under a vein visualizer, which is located proximal to the previously marked functional lymphatic collecting vessel, <http://links.lww.com/PRS/C664>. See Video, Supplemental Digital Content 3, which demonstrates how a reflux-free and a reflux-positive vein behaved with the milking test under a vein visualizer, <http://links.lww.com/PRS/C665>.)

RESULTS

In the experimental group, a total of 12 of 13 veins (92 percent sensitivity) preselected by the VeinViewer were confirmed to be reflux-free intraoperatively during lymphaticovenous anastomosis. In the control group, only 21 of 56 veins (37.5 percent sensitivity) showed no venous reflux. Statistical analysis with the chi-square test showed $p < 0.001$ (number needed to treat = 2.706).

DISCUSSION

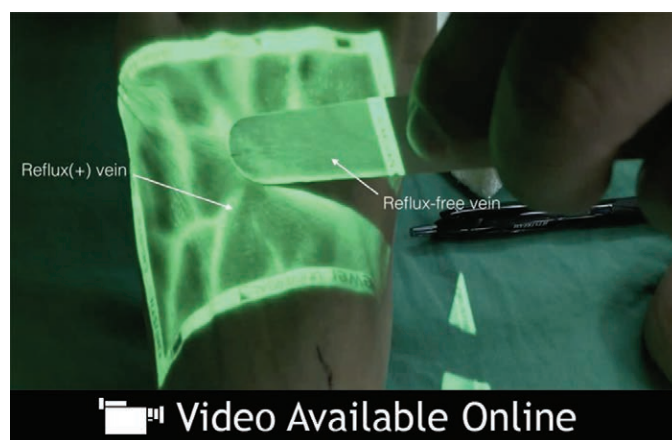
More than one in five women who are breast cancer survivors will eventually suffer from upper limb lymphedema.²⁰ The rate of gynecologic cancer survivors developing lower limb lymphedema ranged from 11.1 to 45.2 percent.^{21–25} To solve this universal health problem, the first animal study using lymphaticovenous anastomosis to treat lymphedema was reported in 1963,²⁶ which was followed by Yamada¹ and O'Brien et al.²⁷ in



Video 2. Supplemental Digital Content 2 demonstrates how to find a reflux-free vein with the milking test under a vein visualizer, which is located proximal to the previously marked functional lymphatic collecting vessel, <http://links.lww.com/PRS/C664>.

treating human patients. Because of the small size (0.3 to 0.8 mm) of lymphatic collecting vessels, the supermicrosurgical technique for lymphaticovenous anastomosis was first introduced and popularized by Koshima et al.^{28–30} With the application and advancement of indocyanine green, it brought revolutionary changes to the diagnosis,^{6,15,31–37} staging,^{33,34,38} and identification of functional lymphatic collecting vessels for lymphedema.^{5,8–10,12,17–19,39,40} As for the identification of small recipient veins for lymphaticovenous anastomosis, ultrasound,⁴¹ Doppler ultrasound,^{42,43} computed tomographic venography, and magnetic resonance venography⁴⁴ can identify only the location. The use of a noninvasive vein visualizer to locate recipient veins for lymphaticovenous anastomosis was introduced by Mihara et al.^{10,11,19} However, no publication has yet to discuss the much needed information regarding a “reflux-free” recipient vein.

By using a commercially available, noninvasive “vein visualizer,” similar to what Mihara et al.^{10,11} have used, this study took one step further: the vein visualizer was used not only for recipient vein localization, but also for selecting a reflux-free vein simultaneously. The instantaneous, live image from the vein visualizer enables the use of the milking test to identify an ideal reflux-free vein. A significant difference ($p < 0.001$) was found for the identification of reflux-free recipient vein with and without the vein visualizer, such as in the control group. The advantages for having the locations of



Video 3. Supplemental Digital Content 3 demonstrates how a reflux-free and a reflux-positive vein behaved with the milking test under a vein visualizer, <http://links.lww.com/PRS/C665>.

both functional lymphatic collecting vessels and reflux-free recipient veins preoperatively are as follows: (1) preoperatively plan for the incision site, allowing for a smaller incision; (2) predetermine the orientation of lymphaticovenous anastomosis (e.g., end-to-end, end-to-side, side-to-end, or side-to-side); (3) reduce the operative time, because of less time needed for exploration; (4) improve surgical outcome, mainly because of better long-term lymphaticovenous anastomosis patency rate; and (5) reduce the need for valvuloplasty.^{4,45} The efficiency of using a vein visualizer for identifying a reflux-free vein is also demonstrated by a number needed to treat of 2.706, showing that it is highly efficient. However, there are limitations to finding a reflux-free vein with a vein visualizer. Because of its limitation as to the depth of superficial vein it can detect, it can be used only for mild lymphedema cases, and reserved for anatomical locations such as dorsal hand/foot, wrist and elbow. Despite this limitation, the use of a vein visualizer is easy, is associated with a short learning curve, and offers an ideal solution for identifying a reflux-free vein in suitable patients.

CONCLUSION

The odds of identifying reflux-free veins can be significantly increased with the use of a vein visualizer.

Johnson Chia-Shen Yang, M.D.

Kaohsiung Chang Gung Memorial Hospital
123 Dapi Road, Niasong District
Kaohsiung, Taiwan 833
johnson.c.yang@gmail.com

REFERENCES

1. Yamada Y. The studies on lymphatic venous anastomosis in lymphedema. *Nagoya J Med.* 1969;32:1–21.
2. Wardhan R, Shelley K. Peripheral venous pressure waveform. *Curr Opin Anaesthesiol.* 2009;22:814–821.
3. Munn LL. Mechanobiology of lymphatic contractions. *Semin Cell Dev Biol.* 2015;38:67–74.
4. Yamamoto T, Koshima I. Neo-valvuloplasty for lymphatic supermicrosurgery. *J Plast Reconstr Aesthet Surg.* 2014;67:587–588.
5. Mihara M, Murai N, Hayashi Y, et al. Using indocyanine green fluorescent lymphography and lymphatic-venous anastomosis for cancer-related lymphedema. *Ann Vasc Surg.* 2012;26:278.e1–278.e6.
6. Ogata F, Azuma R, Kikuchi M, Koshima I, Morimoto Y. Novel lymphography using indocyanine green dye for near-infrared fluorescence labeling. *Ann Plast Surg.* 2007;58:652–655.
7. Yamamoto T, Yamamoto N, Azuma S, et al. Near-infrared illumination system-integrated microscope for supermicrosurgical lymphaticovenular anastomosis. *Microsurgery.* 2014;34:23–27.
8. Yamamoto T, Yamamoto N, Numahata T, et al. Navigation lymphatic supermicrosurgery for the treatment of cancer-related peripheral lymphedema. *Vasc Endovascular Surg.* 2014;48:139–143.
9. Yamamoto T, Yoshimatsu H, Koshima I. Navigation lymphatic supermicrosurgery for iatrogenic lymphorrhea: Supermicrosurgical lymphaticolymphatic anastomosis and lymphaticovenular anastomosis under indocyanine green lymphography navigation. *J Plast Reconstr Aesthet Surg.* 2014;67:1573–1579.
10. Mihara M, Hara H, Kikuchi K, et al. Scarless lymphatic venous anastomosis for latent and early-stage lymphoedema using indocyanine green lymphography and non-invasive instruments for visualising subcutaneous vein. *J Plast Reconstr Aesthet Surg.* 2012;65:1551–1558.
11. Mihara M, Hara H, Narushima M, et al. Lower limb lymphedema treated with lymphaticovenous anastomosis based on pre- and intraoperative ICG lymphography and non-contact vein visualization: A case report. *Microsurgery.* 2012;32:227–230.
12. Mihara M, Hara H, Shibasaki J, et al. Indocyanine green lymphography and lymphaticovenous anastomosis for

- generalized lymphatic dysplasia with pleural effusion and ascites in neonates. *Ann Vasc Surg*. 2015;29:1111–1122.
13. Mihara M, Seki Y, Hara H, et al. Predictive lymphatic mapping: A method for mapping lymphatic channels in patients with advanced unilateral lymphedema using indocyanine green lymphography. *Ann Plast Surg*. 2014;72:706–710.
 14. Narushima M, Yamamoto T, Ogata F, Yoshimatsu H, Mihara M, Koshima I. Indocyanine green lymphography findings in limb lymphedema. *J Reconstr Microsurg*. 2016;32:72–79.
 15. Ogata F, Narushima M, Mihara M, Azuma R, Morimoto Y, Koshima I. Intraoperative lymphography using indocyanine green dye for near-infrared fluorescence labeling in lymphedema. *Ann Plast Surg*. 2007;59:180–184.
 16. Tashiro K, Shibata T, Mito D, et al. Indocyanine green lymphographic signs of lymphatic collateral formation in lower extremity lymphedema after cancer resection. *Ann Plast Surg*. 2016;77:213–216.
 17. Yamamoto T, Narushima M, Yoshimatsu H, et al. Minimally invasive lymphatic supermicrosurgery (MILS): Indocyanine green lymphography-guided simultaneous multisite lymphaticovenular anastomoses via millimeter skin incisions. *Ann Plast Surg*. 2014;72:67–70.
 18. Yamamoto T, Narushima M, Yoshimatsu H, et al. Dynamic indocyanine green (ICG) lymphography for breast cancer-related arm lymphedema. *Ann Plast Surg*. 2014;73:706–709.
 19. Mihara M, Hara H, Hayashi Y, et al. Upper-limb lymphedema treated aesthetically with lymphaticovenous anastomosis using indocyanine green lymphography and noncontact vein visualization. *J Reconstr Microsurg*. 2012;28:327–332.
 20. DiSipio T, Rye S, Newman B, Hayes S. Incidence of unilateral arm lymphoedema after breast cancer: A systematic review and meta-analysis. *Lancet Oncol*. 2013;14:500–515.
 21. Ki EY, Park JS, Lee KH, Hur SY. Incidence and risk factors of lower extremity lymphedema after gynecologic surgery in ovarian cancer. *Int J Gynecol Cancer* 2016;26:1327–1332.
 22. Hareyama H, Hada K, Goto K, et al. Prevalence, classification, and risk factors for postoperative lower extremity lymphedema in women with gynecologic malignancies: A retrospective study. *Int J Gynecol Cancer* 2015;25:751–757.
 23. Biglia N, Librino A, Ottino MC, Panuccio E, Daniele A, Chahin A. Lower limb lymphedema and neurological complications after lymphadenectomy for gynecological cancer. *Int J Gynecol Cancer* 2015;25:521–525.
 24. Achouri A, Huchon C, Bats AS, Bensaid C, Nos C, Lécuru F. Complications of lymphadenectomy for gynecologic cancer. *Eur J Surg Oncol*. 2013;39:81–86.
 25. Deura I, Shimada M, Hirashita K, et al. Incidence and risk factors for lower limb lymphedema after gynecologic cancer surgery with initiation of periodic complex decongestive physiotherapy. *Int J Clin Oncol*. 2015;20:556–560.
 26. Laine J, Howard J. Experimental lymphaticovenous anastomosis. *Surg Forum* 1963;14:111–112.
 27. O'Brien BM, Sykes P, Threlfall GN, Browning FS. Microlymphaticovenous anastomoses for obstructive lymphedema. *Plast Reconstr Surg*. 1977;60:197–211.
 28. Koshima I, Inagawa K, Urushibara K, Moriguchi T. Supermicrosurgical lymphaticovenular anastomosis for the treatment of lymphedema in the upper extremities. *J Reconstr Microsurg*. 2000;16:437–442.
 29. Koshima I, Nanba Y, Tsutsui T, Takahashi Y, Itoh S. Long-term follow-up after lymphaticovenular anastomosis for lymphedema in the leg. *J Reconstr Microsurg*. 2003;19:209–215.
 30. Koshima I, Nanba Y, Tsutsui T, Takahashi Y, Itoh S, Fujitsu M. Minimal invasive lymphaticovenular anastomosis under local anesthesia for leg lymphedema: Is it effective for stage III and IV? *Ann Plast Surg*. 2004;53:261–266.
 31. Yamamoto T, Iida T, Matsuda N, et al. Indocyanine green (ICG)-enhanced lymphography for evaluation of facial lymphoedema. *J Plast Reconstr Aesthet Surg*. 2011;64:1541–1544.
 32. Yamamoto T, Matsuda N, Doi K, et al. The earliest finding of indocyanine green lymphography in asymptomatic limbs of lower extremity lymphedema patients secondary to cancer treatment: The modified dermal backflow stage and concept of subclinical lymphedema. *Plast Reconstr Surg*. 2011;128:314e–321e.
 33. Yamamoto T, Narushima M, Doi K, et al. Characteristic indocyanine green lymphography findings in lower extremity lymphedema: The generation of a novel lymphedema severity staging system using dermal backflow patterns. *Plast Reconstr Surg*. 2011;127:1979–1986.
 34. Yamamoto T, Yamamoto N, Doi K, et al. Indocyanine green-enhanced lymphography for upper extremity lymphedema: A novel severity staging system using dermal backflow patterns. *Plast Reconstr Surg*. 2011;128:941–947.
 35. Mihara M, Hara H, Araki J, et al. Indocyanine green (ICG) lymphography is superior to lymphoscintigraphy for diagnostic imaging of early lymphedema of the upper limbs. *PLoS One* 2012;7:e38182.
 36. Hara H, Mihara M, Seki Y, Todokoro T, Iida T, Koshima I. Comparison of indocyanine green lymphographic findings with the conditions of collecting lymphatic vessels of limbs in patients with lymphedema. *Plast Reconstr Surg*. 2013;132:1612–1618.
 37. Yamamoto T, Narushima M, Yoshimatsu H, et al. Indocyanine green velocity: Lymph transportation capacity deterioration with progression of lymphedema. *Ann Plast Surg*. 2013;71:591–594.
 38. Mihara M, Hayashi Y, Hara H, et al. High-accuracy diagnosis and regional classification of lymphedema using indocyanine green fluorescent lymphography after gynecologic cancer treatment. *Ann Plast Surg*. 2014;72:204–208.
 39. Mihara M, Hara H, Araki J, Narushima M, Iida T, Koshima I. Treatment of hand lymphedema with free flap transfer and lymphangiogenesis analysis after hand replantation using indocyanine green (ICG) lymphography and histological analysis. *J Plast Reconstr Aesthet Surg*. 2013;66:e338–e340.
 40. Yamamoto T, Yoshimatsu H, Yamamoto N, Narushima M, Iida T, Koshima I. Side-to-end lymphaticovenular anastomosis through temporary lymphatic expansion. *PLoS One* 2013;8:e59523.
 41. Toyota K. Ultrasound examination for lower extremity deep vein thrombosis (in Japanese). *Masui* 2014;63:975–981.
 42. Singal AK, Ahmad M, Soloway RD. Duplex Doppler ultrasound examination of the portal venous system: An emerging novel technique for the estimation of portal vein pressure. *Dig Dis Sci*. 2010;55:1230–1240.
 43. Pennell RC, Mantese VA, Westfall SG. Duplex scan for deep vein thrombosis: Defining who needs an examination of the contralateral asymptomatic leg. *J Vasc Surg*. 2008;48:413–416.
 44. Zhang LJ, Wu X, Yang GF, et al. Three-dimensional contrast-enhanced magnetic resonance venography for detection of renal vein thrombosis: Comparison with multidetector CT venography. *Acta Radiol*. 2013;54:1125–1131.
 45. Akita S, Mitsukawa N, Kuriyama M, et al. External valvuloplasty for subcutaneous small veins to prevent venous reflux in lymphaticovenular anastomosis for lower extremity lymphedema. *Plast Reconstr Surg*. 2013;132:1008–1014.